


CASE REPORT

Open Access



# Management of breech presentation with a large pelvic hydatid cyst in late pregnancy in Tibet: a case report

Ping Li<sup>1</sup>, Yang Wang<sup>2</sup>, Qi Yang<sup>3</sup>, Ma Ni<sup>4</sup>, Jianhui Fan<sup>1</sup> and Zeping Huang<sup>5\*</sup> 

## Abstract

**Background:** Hydatid cystic disease (HCD) is primarily a disease of sheep and cattle. Human beings are accidental hosts. It is prevalent in the Tibet Autonomous Region (TAR) of China. In pregnancy, it can cause many complications.

**Case presentation:** We present a multigravida with breech presentation at 37 weeks of pregnancy in whom a large pelvic hydatid cyst and multiple hepatic hydatids were diagnosed by ultrasonography. The large pelvic hydatid cyst was drained through the posterior fornix under the guidance of ultrasound, and an external cephalic version was performed. A healthy baby was delivered vaginally with head presentation at term.

**Conclusion:** HCD during pregnancy presents with management difficulty. It is important to formulate individualized treatment plans according to the actual situation of the patient and the local level of treatment.

**Keywords:** Hydatid cystic disease, Pregnancy, Management, Tibet

## Background

Hydatid cystic disease (HCD) is a zoonotic infection of sheep and cattle caused by the larval stage of the tapeworm *Echinococcus granulosus* (*E. granulosus*) [1]. Humans are infected by ingestion of food contaminated with the eggs of *E. granulosus* [1]. HCD is distributed worldwide and is more prevalent in rural areas with poor living conditions and poor sanitation facilities where sheep, dogs and humans live in close contact [2]. The Tibet Autonomous Region (TAR) of China is reported to be one of the most serious endemic regions for HCD worldwide [3]. Women are at higher risk of HCD than men in this area since women perform the major housework, including feeding dogs, grazing animals, milking and collecting cow dung, increasing their exposure to the

eggs of *E. granulosus* [4]. Currently, free screening and treatment of hydatid disease are performed in local areas every year. However, due to the factors of personal health care awareness, lifestyle and geographical environment, hydatid disease remains a major public health problem in the TAR.

During pregnancy, the diagnosis of HCD is much more important because a decrease in cellular immunity can cause a rapid increase in parasitic growth, and the cysts enlarge [5]. HCD can cause some complications in pregnancy, which vary depending on the site and size of the cyst. Here, we report a case of a large pelvic hydatid cyst with breech presentation who was admitted to a secondary hospital at late pregnancy in the TAR.

## Case presentation

A 19-year-old woman, gravida 2, para 1, was admitted to a secondary hospital at 37 weeks of gestation with breech presentation. Her pregnancy was complicated by multiple hepatic hydatids (the largest cyst: 6.0\*4.3 cm) (see Fig. 1) and a large pelvic hydatid cyst (10.0\*8.2 cm)

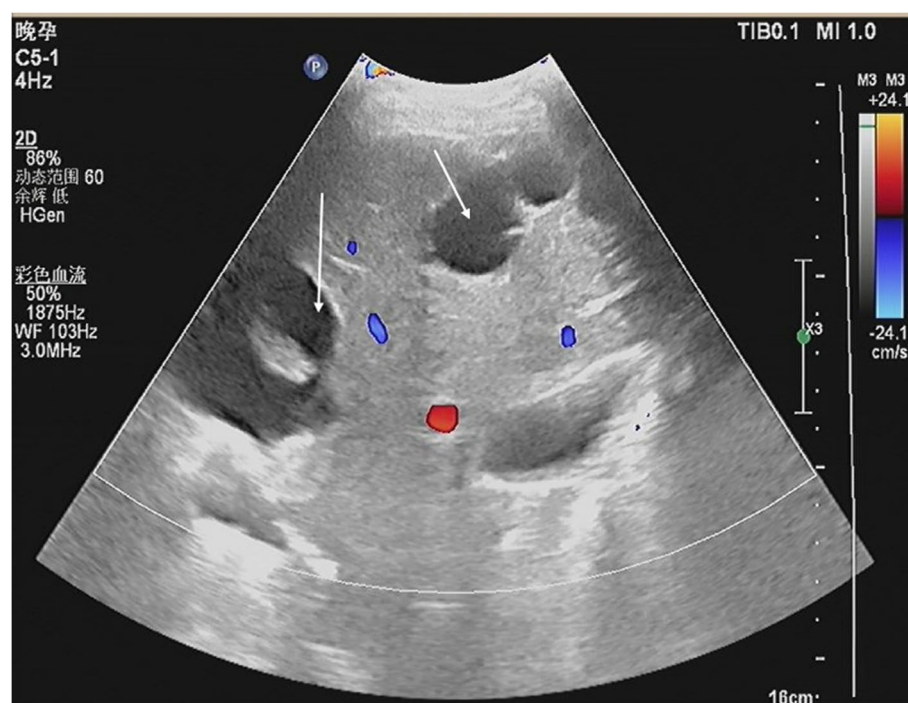
\*Correspondence: hzep@mail.sysu.edu.cn

<sup>5</sup> Department of Ultrasonography, the Third Affiliated Hospital of Sun Yat-Sen University, No. 600, Tianhe road, 510630 Guangzhou, China

Full list of author information is available at the end of the article



© The Author(s) 2022. **Open Access** This article is licensed under a Creative Commons Attribution 4.0 International License, which permits use, sharing, adaptation, distribution and reproduction in any medium or format, as long as you give appropriate credit to the original author(s) and the source, provide a link to the Creative Commons licence, and indicate if changes were made. The images or other third party material in this article are included in the article's Creative Commons licence, unless indicated otherwise in a credit line to the material. If material is not included in the article's Creative Commons licence and your intended use is not permitted by statutory regulation or exceeds the permitted use, you will need to obtain permission directly from the copyright holder. To view a copy of this licence, visit <http://creativecommons.org/licenses/by/4.0/>. The Creative Commons Public Domain Dedication waiver (<http://creativecommons.org/publicdomain/zero/1.0/>) applies to the data made available in this article, unless otherwise stated in a credit line to the data.



**Fig. 1** Sonography at 37 weeks of gestation. Multiple hepatic hydatids are shown (the largest cyst: 6.0\*4.3 cm) (arrow)

(see Fig. 2). Fetal ultrasound showed that the term of the fetus was approximately 37 weeks [biparietal diameter (BPD): 8.9 cm, abdominal circumference (AC): 31.7 cm, femur length (FL): 67 cm]. Three weeks prior to admission (September 1, 2021), the patient felt distended and presented at the hospital, and at that time, it was also her first antenatal examination during this pregnancy. An obstetric ultrasound was performed, and hepatic and pelvic hydatids were found during the scan (see Fig. 3). The size of the pelvic hydatid cyst did not change over these weeks (9.5\*8.6 cm). Three years earlier, she delivered her first baby at home. Two years earlier, she was screened for local endemic diseases and found to have hepatic and abdominopelvic hydatid disease and underwent surgical treatment. Since then, due to a lack of conscientiousness for medical care and her living in remote pastoral areas, she did not have regular reexaminations or medication.

Ultrasound revealed that the pelvic hydatid cyst was located posterior to the uterus as a bulge in the posterior fornix (see Fig. 3). Vaginal and rectal examinations confirmed the mass to be posterior to the uterus and anterior to the rectum. Other laboratory tests, including routine blood examination, C-reactive protein, and liver and kidney function tests performed after admission, were normal.

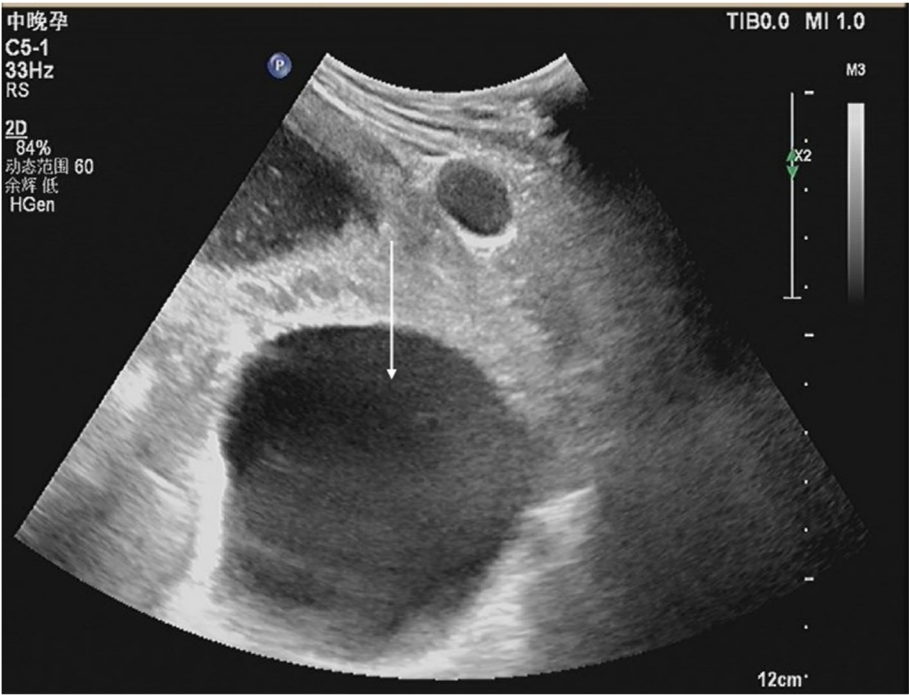
The woman declined Caesarean section and truly wanted natural delivery, so we devised a management

plan according to her situation. Since a large cyst might lead to labor obstruction and abnormal fetal presentation and be more prone to rupture in late pregnancy, we chose to drain the cyst through the posterior fornix under the guidance of transabdominal ultrasound (see Fig. 4a and b; Video 1) (draining out approximately 400 ml of liquid). After the cyst disappeared, the patient was carefully observed for half of the day, including bleeding, fetal movement and uterine contraction. After confirming that the patient did not have any complications, we successfully performed an external cephalic version. After two days of observation, the woman was discharged because she showed no signs of labor. One week later, the woman delivered a baby boy naturally with head presentation in our hospital and was advised to undertake medical management for HCD follow-up.

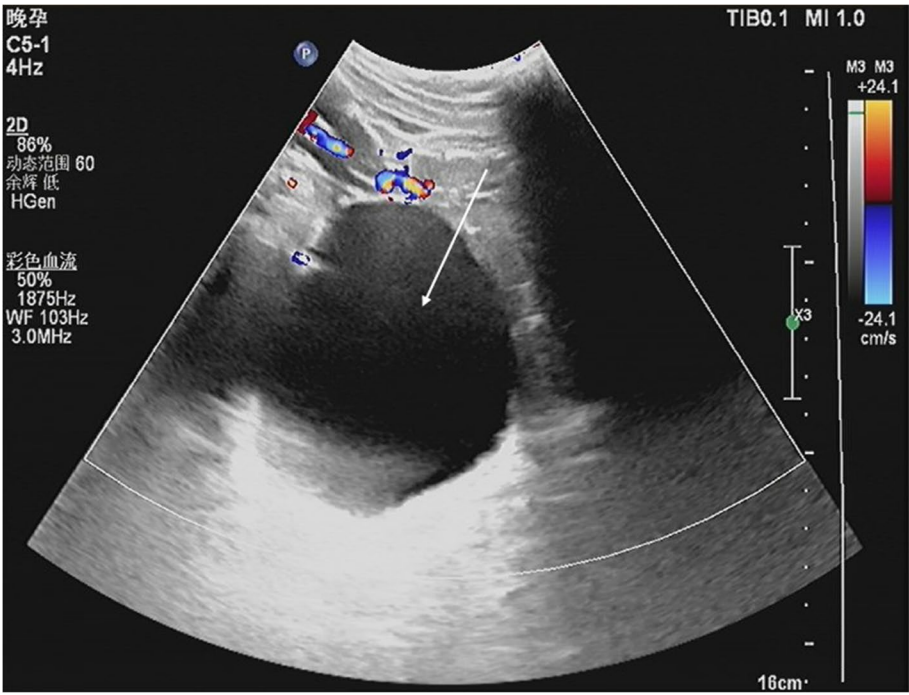
## Discussion and conclusions

HCD in TAR is prevalent due to living habits, living in remote pastoral areas, traffic inconvenience, and lack of conscientiousness for medical care [6, 7]. Since these personal and environmental factors are unlikely to change in a short time, HCD has remained a major public health problem for local people for some time.

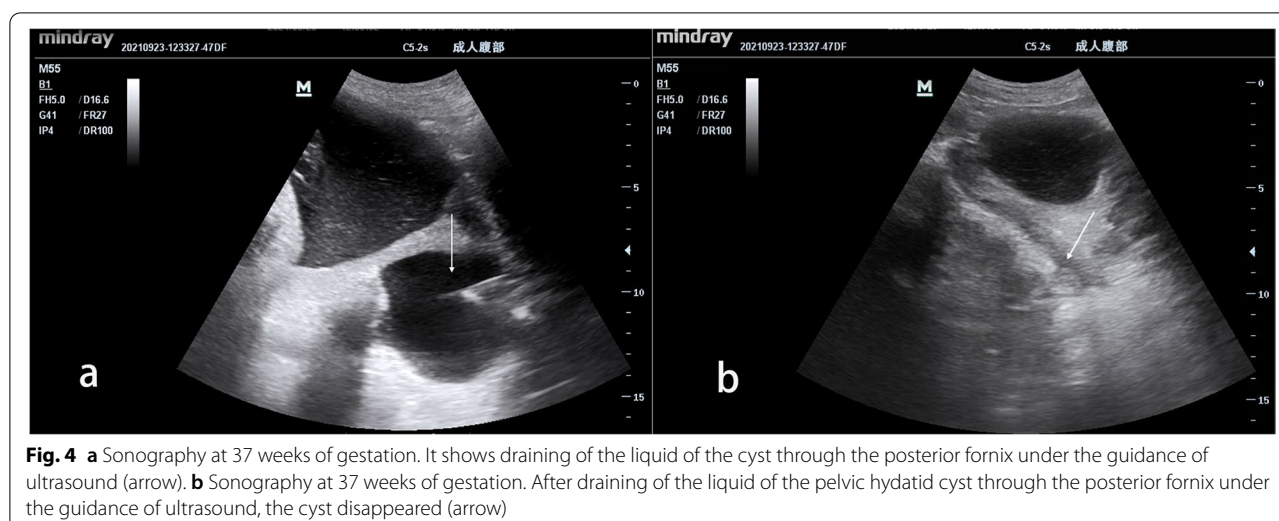
HCD can be located in the liver (63%), lungs (25%), muscles (5%), bones (3%), kidneys (2%), spleen (1%), and other sites (1%) [8]. It is sometimes nonsymptomatic and



**Fig. 2** Sonography at 37 weeks of gestation. A large pelvic hydatid cyst is shown (10.0\*8.2 cm) (arrow)



**Fig. 3** Sonography at 34 weeks of gestation. A large pelvic hydatid cyst is shown (9.5\*8.6 cm) (arrow)



sometimes can cause complications, and these factors are closely related to the site and size of the cyst. The complications are mainly caused by compression, irritation or rupture of the cyst. If it is located in the liver, it can cause pain, vomiting, pruritus, jaundice and emergence of a mass [9]. If it is located in the cerebrum, it can commonly cause headache, vomiting, seizures and visual disturbances [10]. During pregnancy, if HCD is located in the pelvis, it can cause torsion, rupture, premature delivery, and labor obstruction [11, 12].

Many studies have suggested that ultrasound is the gold-standard screening test for HCD since it can show the number of cysts and their locations and relationships with other structures [9, 12]. Specific immunoglobulin determination can help to confirm the diagnosis. In addition, MRI is also a good examination method. However, advanced examination and medical facilities are relatively scarce in primary hospitals, and the cost is high. Therefore, ultrasound is also the most commonly used screening method for HCD in the TAR.

The ideal treatment for HCD has not been fully determined [13], and management during pregnancy is also a problem. Surgical therapy is a common approach, but it is difficult to perform during pregnancy since it can increase intraoperative morbidity due to the enlarged gravid uterus and pose a risk of miscarriage or preterm labor. Percutaneous treatment is a well-established procedure in HCD [14, 15], and it is also an effective treatment during pregnancy [16, 17]. However, there is a risk of anaphylaxis during the procedure [18]. For medical treatment, albendazole is a commonly used drug for echinococcosis [1]. It can reduce the size and number of cysts. The average time for a cyst to shrink or disappear using drugs is approximately 6–12 months [19, 20]. During pregnancy, the use of the drug remains controversial. It has been shown to

have teratogenic effects in experimental studies [21]. In recent years, it has been reported that it is not absolutely contraindicated during pregnancy and can be used in the second and third trimesters if treatment is necessary [1]. Therefore, the management of HCD should be individualized. In the TAR, with the improvement of diagnosis and treatment in recent years, medical treatment of HCD is widely available, and surgical therapy can be administered in most tertiary hospitals and some secondary hospitals.

In this case, the patient truly hoped for vaginal delivery. However, the large pelvic hydatid cyst obstructed the birth canal, and the fetus was mispresented. The patient had been operated on for abdominal echinococcosis before, and the adhesion might have been serious. Hence, even if Caesarean section is performed, the difficulty might increase, especially in secondary hospitals, where the form of medical care provided to patients is affected by geographical location due to how long it takes to transfer patients, the nonavailability of blood banks and the lack of advanced medical facilities. Based on the location of the cyst, we modified the percutaneous treatment and opted to drain the cyst through the posterior fornix under the guidance of transabdominal ultrasound. There have been few reports of treatment adopting this procedure. After confirming that the patient did not have any complications, we performed an external cephalic version for the woman, and she finally had a successful vaginal delivery. This individualized treatment not only met the requirements of the patient but also caused minimal damage to the patient and was costless and effective.

In conclusion, HCD during pregnancy presents with management difficulty. It is important to formulate individualized treatment plans according to the actual situation of the patient and the local level of treatment.



## Abbreviations

HCD: hydatid cystic disease; TAR: Tibet Autonomous Region; BPD: biparietal diameter; AC: abdominal circumference; FL: femur length.

## Supplementary Information

The online version contains supplementary material available at <https://doi.org/10.1186/s12884-022-05180-2>.

**Additional file 1: Video 1.** Draining the cyst through the posterior fornix under the guidance of transabdominal ultrasound.

## Acknowledgements

The authors thank all of the doctors working in the Department of Obstetrics and Gynecology of the Third Affiliated Hospital of Sun Yat-sen University for their great help in this study.

## Authors' contributions

PL contributed to the study conception, clinical data analysis, and manuscript preparation and approved the manuscript. YW: contributed to the laboratory examination and approval of the final manuscript. QY: contributed to the drug consultation and approval of the final manuscript. MN contributed to the medical record collation and approved the manuscript. JHF: performed manuscript preparation and approval of the final manuscript. ZPH contributed to the ultrasound examination, manuscript preparation, and approval of the final manuscript. All of the authors contributed to the article and approved the submitted version.

## Funding

This work was supported by research grants from the Medical Scientific Research Foundation of Guangdong Province (A2021049). The funder played no role in the design of the study, data collection and analysis, or presentation of the results.

## Availability of data and materials

The data and materials of this study are not publicly available due to patient privacy and the hospital data management policy but are available from the corresponding author upon reasonable request. Such requests must also be approved by the local hospital.

## Declarations

### Ethics approval and consent to participate

We confirm that all of the experimental protocols were approved and consented to by the Human Research Ethics Committee of Chaya County People's Hospital.

### Consent for publication

Informed consent was obtained for the publication of any identifying images or other personal or clinical details of the patient that might compromise anonymity when this manuscript was written. Consent was obtained from the patient, and proof can be provided at any time.

### Competing interests

The authors declare that they have no conflicts of interest.

### Author details

<sup>1</sup>Department of Obstetrics and Gynecology, the Third Affiliated Hospital of Sun Yat-Sen University, Guangzhou, China. <sup>2</sup>Laboratory of Biochemistry, the Third Affiliated Hospital of Sun Yat-Sen University, Guangzhou, China. <sup>3</sup>Department of Pharmacy, the Third Affiliated Hospital of Sun Yat-Sen University, Guangzhou, China. <sup>4</sup>Department of Obstetrics and Gynecology, Chaya County People's Hospital, Tibet, China. <sup>5</sup>Department of Ultrasonography, the Third Affiliated Hospital of Sun Yat-Sen University, No. 600, Tianhe road, 510630 Guangzhou, China.

Received: 9 March 2022 Accepted: 3 November 2022

Published online: 20 November 2022

## References

- McManus DP, Zhang W, Li J, Bartley PB. Echinococcosis Lancet. 2003;362(9392):1295–304.
- Rojo-Vazquez FA, Pardo-Lledias J, Francos-Von Hunefeld M, et al. Cystic echinococcosis in Spain: current situation and relevance for other endemic areas in Europe. *PLoS Negl Trop Dis*. 2011;5(1):e893.
- Deplazes P, Rinaldi L, Alvarez Rojas CA, et al. Global Distribution of Alveolar and Cystic Echinococcosis. *Adv Parasitol*. 2017;95:315–493.
- Li B, Quzhen G, Xue CZ, et al. Epidemiological survey of echinococcosis in Tibet Autonomous Region of China. *Infect Dis Poverty*. 2019;8(1):29.
- Can D, Oztekin O, Oztekin O, Tinar S, Sancı M. Hepatic and splenic hydatid cyst during pregnancy: a case report. *Arch Gynecol Obstet*. 2003;268(3):239–40.
- Wang Y, Ma BC, Wang LY, Quzhen G, Pang HS. Effects of management of infection source of echinococcosis in Linzhi, Tibet Autonomous Region of China. *Infect Dis Poverty*. 2021;10(1):25.
- Ma T, Jiang D, Quzhen G, et al. Factors influencing the spatial distribution of cystic echinococcosis in Tibet, China. *Sci Total Environ*. 2021;754:142229.
- Topley MWM. Microbiology and microbial infections: medical parasitology. 10th ed. 2005. Hodder Arnold. 677–702.
- Keong B, Wilkie B, Sutherland T, Fox A. Hepatic cystic echinococcosis in Australia: an update on diagnosis and management. *ANZ J Surg*. 2018;88(1–2):26–31.
- Benhayoune O, Makhchoune M, Jehri A, Yassine Haouas M, Naja A, Lakhdar A. Cerebral hydatid cyst during pregnancy: A case report. *Ann Med Surg (Lond)*. 2021;63:102161.
- Tyagi S, Singh C, Tripathi R, Mala Y. Pregnancy complicated by abdominopelvic hydatid disease. *BMJ Case Rep*. 2012;bcr2012007880. <https://doi.org/10.1136/bcr-2012-007880>. PMID: 23230263; PMCID: PMC4545115.
- Manterola C, Espinoza R, Muñoz S, et al. Abdominal echinococcosis during pregnancy: clinical aspects and management of a series of cases in Chile. *Trop Doct*. 2004;34(3):171–3.
- Dehkordi AB, Sanei B, Yousefi M, et al. Albendazole and Treatment of Hydatid Cyst: Review of the Literature. *Infect Disord Drug Targets*. 2019;19(2):101–4.
- Gomez I, Gavara C, López-Andújar R, Belda Ibáñez T, et al. Review of the treatment of liver hydatid cysts. *World J Gastroenterol*. 2015;21(1):124–31.
- Giorgio A, Calisti G, de Stefano G, Farella N, Scognamiglio U, Giorgio V. Percutaneous treatment of hydatid liver cysts: an update. *Recent Pat Antiinfect Drug Discov*. 2012;7(3):231–6.
- Ustunsoz B, Ugurel MS, Uzar AI, Duru NK. Percutaneous treatment of hepatic hydatid cyst in pregnancy: long-term results. *Arch Gynecol Obstet*. 2008;277(6):547–50.
- Musaev GK, Sharipov RK, Fatyanova AS, Levkin VV, Ishchenko AI, Zuyev VM. [Echinococcosis and pregnancy: approaches to the treatment]. *Khirurgiia (Mosk)*. 2019;5:38–41.
- Ustünsöz B, Alemdaroğlu A, Bulakbaşı N, Uzar AI, Duru NK. Percutaneous treatment of hepatic hydatid cyst in pregnancy. *Arch Gynecol Obstet*. 1999;262(3–4):181–4.
- Baykaner MK, Doğulu F, Öztürk G, Edali N, Tali T. A viable residual spinal hydatid cyst cured with albendazole. Case report. *J Neurosurg*. 2000;93(1 Suppl):142–4.
- Kuyumcu ME, Yesil Y, Etgül S, et al. Inoperable isolated cardiac hydatid cyst controlled with albendazole in an older adult with dementia. *Age Ageing*. 2013;42(6):812–4.
- Guidelines for treatment of cystic and alveolar echinococcosis in humans. WHO Informal Working Group on Echinococcosis. *Bull World Health Organ*. 1996;74(3):231–42.

## Publisher's Note

Springer Nature remains neutral with regard to jurisdictional claims in published maps and institutional affiliations.